

Left Ovary-Containing Hernia of the Canal of Nuck and Right Inguinal Hernia with Small Bowel Loops in a 12-Day-Old Newborn Girl: A Rarity

Reddy Ravikanth*, Kanagasabai Kamalasekar

Department of Radiology, Holy Family Hospital, Thodupuzha, Kerala, India

Dear Editor,

A 12-day-old newborn girl was brought to the Department of Neonatology of our hospital for persisting right inguinal swelling which developed on postnatal day 1 and new appearance of left inguinal swelling on postnatal day 11. Ultrasonographic evaluation of the bilateral groins was done which revealed an echogenic ovoid, solid mass containing cysts in the left inguinal region which is noted to extend to the abdominal cavity through the canal of nuck [Figure 1]. The small cysts are the follicles in the normal ovary. On color Doppler ultrasonography, blood flow was seen in the mass, confirming the presence of ovary as content. Similar mass was visualized in the right inguinal region which contained small bowel loops [Figure 2]. A diagnosis of left ovary-containing inguinal hernia of the canal of nuck and right small bowel loops-containing inguinal hernia was given. The left inguinal mass was movable and further showed color signal pickup on Doppler ultrasonography, thus confirming the viability of the ovary. Similarly, small bowel loops-containing right inguinal hernia was reducible and showed no signs of incarceration. The neonate was conservatively managed and was followed up. For hernias of the canal of nuck, the peritoneal contents, including the bowel, omentum, fluid, and urinary bladder, can herniate into the inguinal canal.^[1] Ultrasonography is an easily applied and highly accurate imaging modality. Ultrasonography with a high-frequency transducer is the imaging modality of choice for evaluating inguinal lesions. It provides excellent spatial resolution and assists in the identification and characterization of inguinal lesions. In the characterization of the hernial contents, the visualization of ovary-like structures containing peripheral cysts on ultrasonography was helpful for the diagnosis of the hernial contents as ovary tissue. Ultrasonographic finding of solid

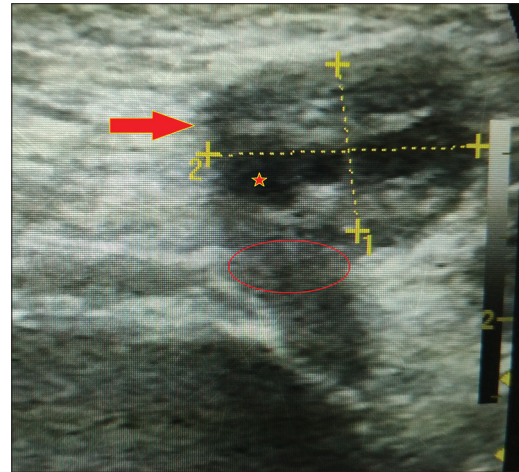


Figure 1: Longitudinal gray-scale ultrasonography showing an echogenic, ovoid, solid mass (arrow) containing cysts in the left inguinal area, which extends to the abdominal cavity through the neck of the canal of nuck (circle). The small cysts are the follicles in the normal ovary (star)

masses containing multiple cysts of varying size is a useful sign for the identification of ovary-containing hernias.^[2] Early diagnosis is important when the hernia contains an ovary because incarceration of the ovary is common. Incarcerated ovaries in neonates are at risk of torsion.^[3] If torsion of the ovary occurs, venous and lymphatic return of the ovary within the canal of nuck is impaired, causing increased swelling and pressure. This is usually accompanied by symptoms such as severe irritability, abdominal pain, and vomiting. Gangrene and tissue necrosis of the ovary supervene if the hernia is not

Address for correspondence: Dr. Reddy Ravikanth,
Department of Radiology, Holy Family Hospital, Thodupuzha - 685 605,
Kerala, India.
E-mail: ravikanthreddy06@gmail.com

Received: 27-09-2018 Accepted: 28-12-2018 Available Online: 21-02-2019

Access this article online

Quick Response Code:



Website:
www.jmuonline.org

DOI:
10.4103/JMU.JMU_96_18

This is an open access journal, and articles are distributed under the terms of the Creative Commons Attribution-NonCommercial-ShareAlike 4.0 License, which allows others to remix, tweak, and build upon the work non-commercially, as long as appropriate credit is given and the new creations are licensed under the identical terms.

For reprints contact: reprints@medknow.com

How to cite this article: Ravikanth R, Kamalasekar K. Left ovary-containing hernia of the canal of nuck and right inguinal hernia with small bowel loops in a 12-day-old newborn girl: A rarity. J Med Ultrasound 2019;27:158-9.

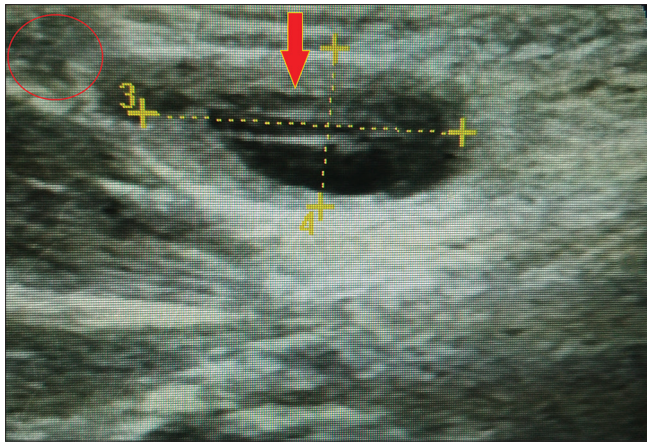


Figure 2: Longitudinal gray-scale ultrasonography showing small bowel loops (arrow) extending into the right inguinal region (circle). The mass was reducible and showed no signs of incarceration

reduced. Ultrasonographic findings of ovarian torsion are an enlarged, mass-like ovary with heterogeneous echogenicity that contains multiple peripheral cysts and no blood flow within the ovary. On the other hand, signs of an incarcerated hernia containing small bowel loops are thickening of the wall of the herniated bowel loop, fluid in the herniated bowel loop, free fluid in the hernial sac, and intra-abdominal bowel dilatation. In conclusion, an ovary-containing hernia of the canal of nuck is a rare type of inguinal mass and a contralateral inguinal hernia with small bowel loops makes it even more rare. Ultrasonography may be helpful in the diagnosis of

ovary-containing hernias of the canal of nuck by the detection of solid masses containing small cysts. Even without signs of strangulation, hernias containing ovaries should be managed with early surgical reduction after the detection of an ovary within the hernial sac.

Declaration of patient consent

The authors certify that they have obtained all appropriate patient consent forms. In the form the patient(s) has/have given his/her/their consent for his/her/their images and other clinical information to be reported in the journal. The patients understand that their names and initials will not be published and due efforts will be made to conceal their identity, but anonymity cannot be guaranteed.

Financial support and sponsorship

Nil.

Conflicts of interest

There are no conflicts of interest.

REFERENCES

1. Yang DM, Kim HC, Kim SW, Lim SJ, Park SJ, Lim JW, *et al.* Ultrasonographic diagnosis of ovary-containing hernias of the canal of Nuck. *Ultrasonography* 2014;33:178-83.
2. Narci A, Korkmaz M, Albayrak R, Sözübir S, Güvenç BH, Köken R, *et al.* Preoperative sonography of nonreducible inguinal masses in girls. *J Clin Ultrasound* 2008;36:409-12.
3. Laing FC, Townsend BA, Rodriguez JR. Ovary-containing hernia in a premature infant: Sonographic diagnosis. *J Ultrasound Med* 2007;26:985-7.